



BENEFICIARY FORM

Name : Sudhanshu Kumar Kamti | Age: 11 Months | Sex: M

Brief details about the Beneficiary:


Sudhanshu Kumar Kamti is a 11months old boy suffering from **Tetralogy Of Fallot** . There are 6 members in the family, his father is the only earning member. Sudhanshu has been advised **TOF Surgery** . The treatment is going to be done in Fortis Escorts Heart Institute and Research Centre Limited, New Delhi, under the supervision of Dr.Krishna.S.Iyer, Executive Director (Paediatric & Congenital Heart Surgery) and Dr.S.Radhakrishnan (Head of Department of Paediatric Cardiology). The total estimate is Rs.3,24,000/- for the Surgery. Sudhanshu's family needs partial support as his family is not in a position to bear the expenses of his treatment.

About the Family

Father's Name	Mr. Narayan Kamati	Age	25	Edu	XIth STD	Occupation	Security Guard
Mother's Name	Mrs. Mira Devi	Age	22	Edu	Xth STD	Occupation	Housewife
Family Members	6	No. of children	1		No. of school going	0	
Earning Members	1	Monthly Income	Rs.13500/-		Belongs to	Bihar	

Medical Treatment


Hospital / Institution's Name :	Fortis Escorts Heart Institute & Research Centre Limited		
Address	Okhla Road, New Delhi - 110025		
Diagnosis	Tetralogy Of Fallot		
Treatment required	TOF Surgery		
Reg. No.	11711924		
Total (approx.) expense of treatment / surgery	Rs.3,24,000/-		


Dr. S. RADHAKRISHNAN
 M.D., D.M.
 Director & HOD Paediatrics &
 Congenital Heart Diseases
 DMC Reg. No. 6642
 Fortis Escorts Heart Institute
 Okhla Road, New Delhi-110025
Sign. of Doctor with Stamp

Reason for which sponsorship required:	Surgery	<input checked="" type="checkbox"/>	Treatment	<input type="checkbox"/>
---	----------------	-------------------------------------	------------------	--------------------------

Declaration

I hereby declare that the information given above is true and I am not in position to afford the treatment expenses


Signature of Parents / Guardian


Authorised Signatory


Diya India Foundation is a Registered Trust

All donations to Diya India Foundation are eligible for deduction under Section 80 G of the Income Tax Act, 1961.

DR. S. RADHAKRISHNAN

MD, DM

Executive Director

PAEDIATRIC & CONGENITAL HEART DISEASE

To,

Diya India Foundation

402, Ansal Majestic TowerG Block, Vikas Puri

New Delhi 110018

Dear Sir/Madam,

This letter is regarding Master Sudhanshu Kamti, 11 months old male, son of Mr. Narayan Kamati was evaluated at Fortis Escorts Heart Institute, New Delhi vide Regn No. 11711924 diagnosed to have Tetralogy of Fallot. He is advised to undergo TOF Surgery. The estimated cost of the surgery is Rs. 3,24,000/-(10 days).

The family is not financially able to bear the whole cost of the surgery. So the family requires financial assistance of Rs 2,64,000/- from Diya India Foundation and the rest i.e. Rs 60,000/- parents will give. Kindly help them in all possible way.

With Best Wishes,



Dr. S. RADHAKRISHNAN

Dr. S. Radhakrishnan
MD, DM
Executive Director
Pediatric & Congenital Heart Disease
DMC Registration number : 6642
Fortis Escorts Heart Institute
Okhla Road, New Delhi 110025



NABH Accredited

Out Patient Record

Please Bring This Record With You



Date of Registration 29/4/22 Registration No. _____

Name SUDHANSHU KUMAR

Age 10^{years} (D.O.B.) 4/7/21 Sex: M F Consultant DR - S. RADHAKRISHNAN

Address _____

Phone No. _____

Booklet No. _____



Okhla Road, New Delhi - 110025 Phones : +91-11-47135000 Fax : +91-11-26825013
Email : contactus.escorts@fortishealthcare.com | Website : www.fortisescorts.in
Please contact in Emergency : +91-11-26825002 | Use Ambulance Helpline : 105010

Date: 29/4/22

SUDHANSHU

Name of Patient

Kumar

Reg. No.

Salient Complaints

WT - 77 kg

HT 69 cm

History

1st B.O / MUD (2.5 kg) / CIAB detected to have (HD) at 9M when murmur detected by Physician for

SpO2: 88 %

HR: 146/min

Weight:

BP: Eusystolic

Pain Score (0-10)

BMI: Low High Within Limits

Systemic Examination

O/E alert active CUS - ESM (+)

Investigations Advised

no h/o of spell

Echo

Treatment Advised

RPA =

= 9 mm

(E = 9.5 mm)

LPA

origin = 4.3 mm

Distal = 6.1 mm

(E = 6.5 mm)

MPA = 4 mm

• Situs Solitus, IVC aorta Dext

• Normal Systemic & Pulmonary venous drainage

• PFO (+) (Bidirectional)

• Laminae inflow

• TOF

• Large malaligned PMUSD (Bidirectional shunting) with anterior deviation of cord

• Severe Pulmonary Stenosis (Supra valvular, valvular and subvalvular) MR 16 = 72 mmHg

Surgical Wreck

Thoracic Aortic Arch Normal origin of coronary confluent Branch PAs

left arch, laminae flow in Aorta

no COA, no PPA, no SVC

• Consultant Sign: [Signature]

ID No.: 96070

Reg. No. - 39569

चाईल्ड हेल्थ क्लिनिक

Dr. Pramod Kumar

M.B.B.S., D.C.H. (PMCH, PATNA)
Ex - Senior Resident
(Chacha Nehru Bal Chikitsalaya New Delhi)
New Born & Child Specialist



डा. प्रमोद कुमार

एम. बी. बी. एस, डी. सी. एच. (पटना मेडिकल कॉलेज)
पूर्व वरिष्ठ चिकित्सक
(चाचा नेहरू बाल चिकित्सालय, नई दिल्ली)
नवजात एवं शिशु रोग विशेषज्ञ

बच्चों के लिए शीशा घर (NICU) की व्यवस्था है।

तमुरिया (रेलवे गुमती के नजदिक), जिला- मुधुबनी, बिहार

रमेश जी - 9570243608, 9110015363, सुशील जी - 9801491551

Name of Patient Sudhanshu kumar Date 14/4/22
Age 10 month Sex Male Weight 7.5kg
Address Hansi

O/E

clo. - Loose stool

- Vomitus

- Fever, cold & cough

CNS- Normal

CHEST- AK clear

CVS- Systemic murmur - Emers on

P/A- Soft

H.R.- 100/m

R.R.- 32/m

CRT- 2s

CRA- gr

SKIN- -

AD

• Syb Taxim - 100/100

2 ml or

• Syb Zincup

5ml or 14 d

• Gnderomax

1d2 - 3 day

• Syb Ondem

2.5ml or 2 day

• Syb Colaman

2.5ml or 1 d

• Syb Montmar

2.5ml or 1 d

• Syb Calpol

2.5ml 5d

▷ C-PAP is used as per

ECHO Doppler

नोट : 1. बच्चों के लिए शीशा घर (NICU) एवं C-PAP की व्यवस्था है। 2. इलाज के दौरान आकस्मिक स्थिति आने पर निकट अस्पताल से सम्पर्क करें। 3. दवा व्यवहार से पहले अवश्य दिखा लें। 4. किसी भी तरह का सर्टिफिकेट के लिए आग्रह नहीं करें। 5. 20 दिन के बाद पुनः परामर्श फी लगेगा।

R



PAROPKAR ECHO CENTRE

SANJEEV REST HOUSE

Near - Honda Agency, VIP Road, Allalpatti, Darbhanga - 846003
Mob. : 9006153256, 8986056806

Patient's Name: - Master Sudhanshu Kumar

Age:- 10/Months, Sex: - Male

Ref. By :- Dr. Pramod Kumar DCH

Date: - 15/April/2022

ECHOCARDIOGRAPHY

MITRAL VALVE: -

Morphology: - AML- Normal/Thickening/Calcification/Flutter/Vegetation/Prolapse/SAM/Doming
PML - Normal/Thickening/Calcification/Prolapse/paradoxical motion/Fixed
Subvalvular deformity present/Absent Score

Doppler: - Normal/Abnormal

Mitral stenosis Present/Absent RR Intervalmsec
EDGA ... Mm/Hg MDG ... mm/Hg MVA ... Mm/Hg
Mitral Regurgitation Absent/Trivial/Mild/Moderate/Severe

TRICUSPID VALVE: -

Morphology: - Normal/Atresia/Thickening/Calcification/Prolapse/Vegetation/Doming

Doppler: - Normal/Abnormal

Tricuspid stenosis Present/Absent RR interval ... msec
EDG ... Mm/Hg MDG ... Mm/Hg
Tricuspid Regurgitation Absent/Trivial/Mild/Moderate/Severe Fragmented Signals
Velocity m/Sec Pred. RSVP- RAPS ... mm/Hg

PULMONARY VALVE: -

Morphology: - Normal/Atresia/Thickening/Doming/Vegetation

Doppler: - Normal/Abnormal Pulmonary stenosis Present/Absent Level
PSG ... Mm/Hg Pulmonary annulus ... mm
Pulmonary Regurgitation Present/Absent
Early diastolic gradient ... Mm/Hg End diastolic gradient ... mm/Hg

AORTIC VALVE: -

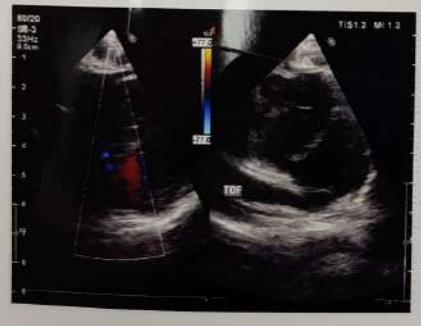
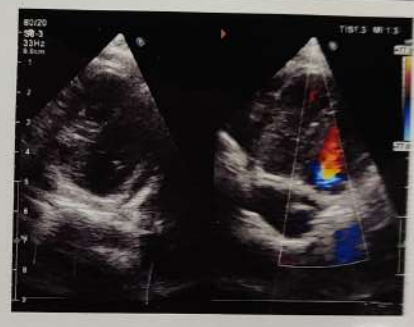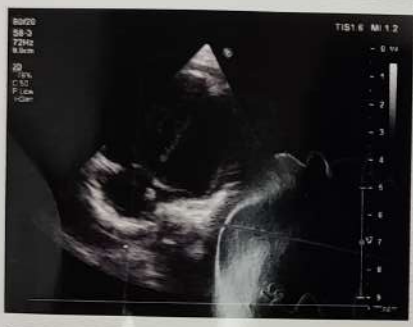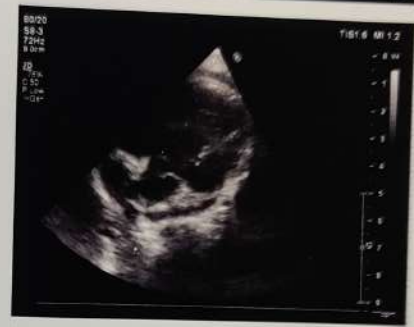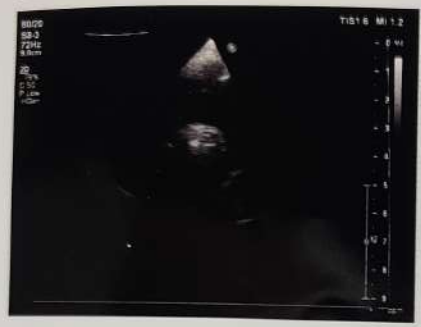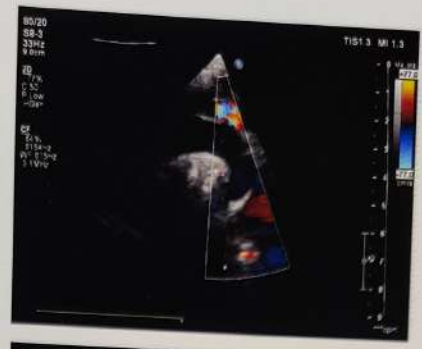
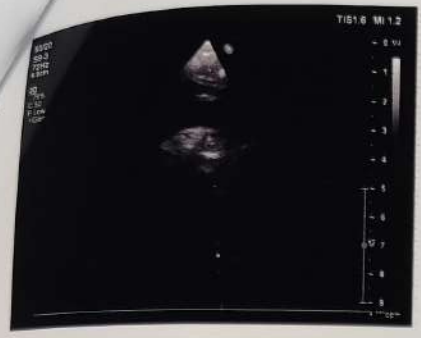
Morphology: - Normal/Thickening/Calcification/Restricted opening/Flutter/Vegetation No. of cusps 1/2/3/4

Doppler: - Normal/Abnormal Aortic stenosis Present/Absent Level
PSG ... Mm/Hg Aortic annulus mm/Hg
Aortic Regurgitation Absent/Trivial/Mild/Moderate/Severe

(Continued Page- 2)

Radiological diagnosis is based on interpretation of shadows produced by normal & abnormal tissues, these are not conclusive & often vary with clinical course of disease or response to treatment. Clinical correlation, Pathological, Biochemical and further Radiological, Investigations (MRI) may be required to reach a final Diagnosis.

THIS REPORT & FILM(S) ARE NOT VALID FOR MEDICOLEGAL PURPOSE



No. 21-22
(21-22)
(19-32 ml)
(7-11 mm/min)
(Up to 5 mm)

